

IMPLANT CASE BLOGS

As most patients hear of the word “Implant”; we have often seen them give incredulous looks ... one can palpate the apprehension and uncertainty ... the indecision in their minds... the innumerable questions that sometimes stay unasked as they feel they are being impolite by questioning too much and those other times when the consultations just don't end...!!!

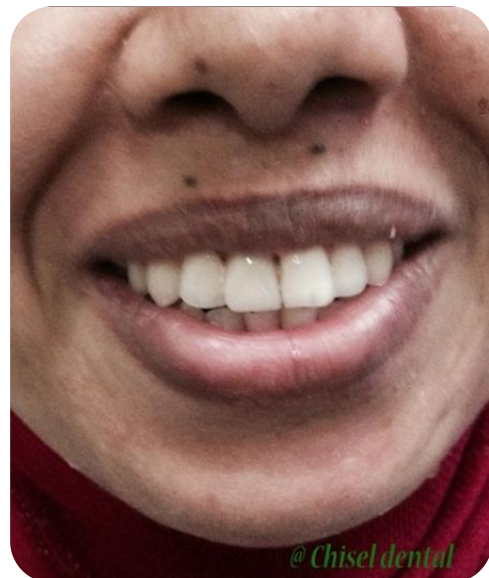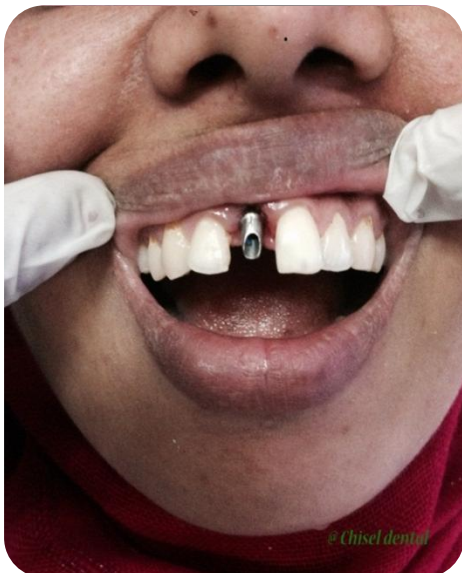Through the years we have discovered that presenting cases visually corresponding to the different situations requiring implants improves understanding of the procedure and brings comfort by demystifying (simplifying) Implants; helping people make a decisive informed choice...

Here are a few case presentations of different scenarios requiring Implant placement and the procedure that goes along with it. You can scroll through to the condition you most identify with and if you are one among those with a zillion different doubts in your minds, hope this helps ... :)

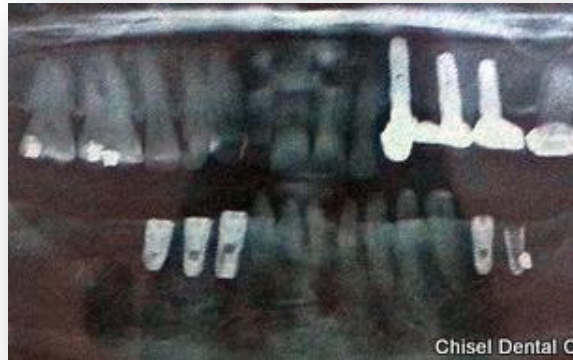SIMPLE IMPLANTS: [Esp. ESTHETIC ZONE IMPLANTS]

Single tooth Immediate Implant:

This is one of the most commonly occurring cases, where a single tooth is lost or removed. Especially for a young individual; going in for an implant holds as much functional importance in preserving the adjacent healthy teeth and preventing bone loss in the area of tooth already lost maintaining facial structure...



Even in an elderly person, single tooth implants help to preserve and increase the life of existing adjacent teeth while acting as an investment for future replacements of multiple teeth too whenever required. **Also implants more importantly helps to preserve the bone around the area of tooth loss resulting in better bone support of adjoining teeth and decreased effects of aging....**



Lower Front teeth Implant:

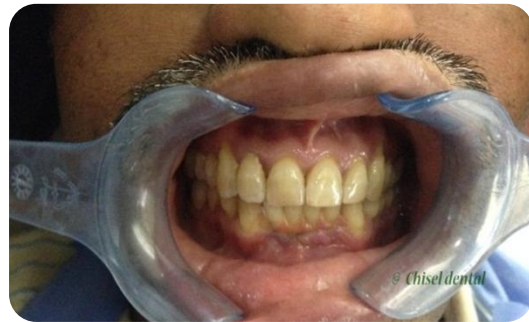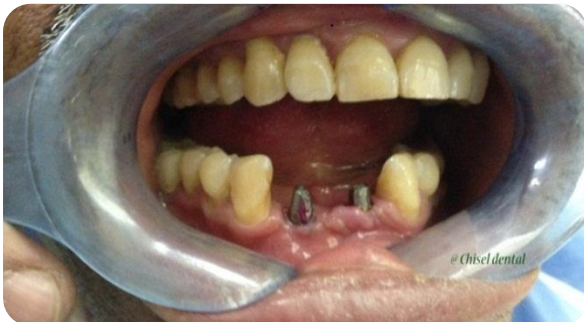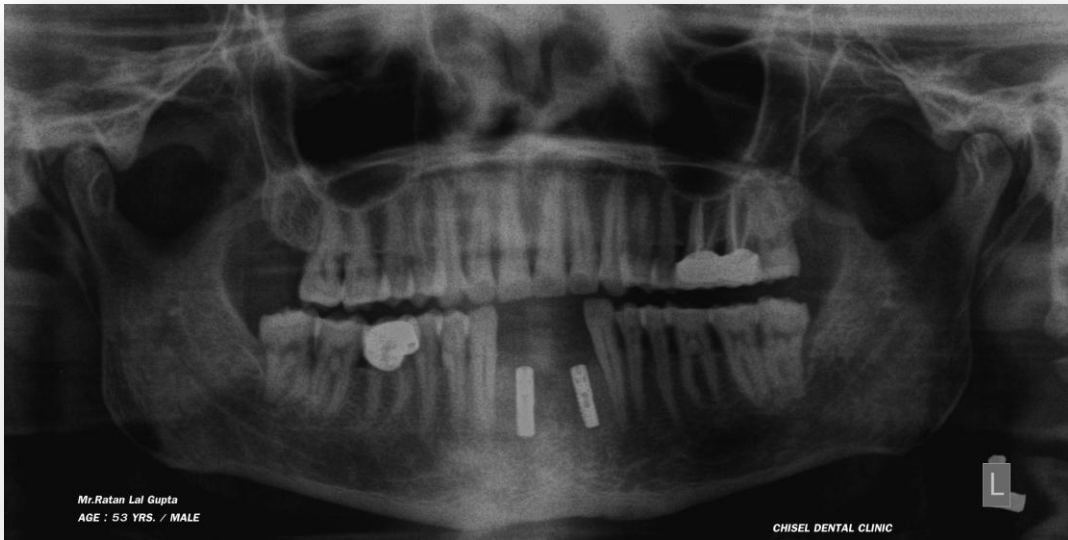
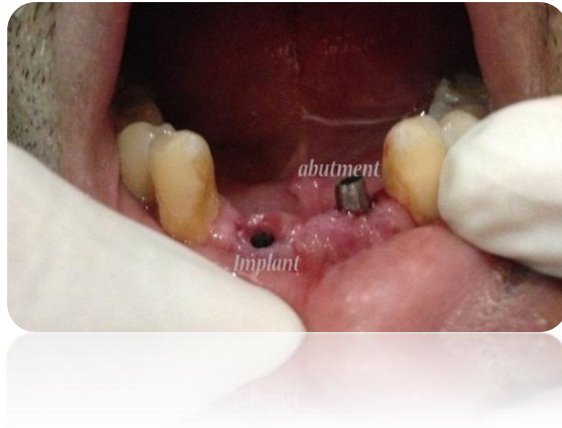This patient, had come down from Kolkata especially for dental treatment with loose mobile front teeth and some decay in his back teeth.

On examination, it was noticed that few teeth required Root canal and few required capping while the lower teeth were too mobile to be saved. Hence, accordingly the treatment was scheduled such that on one day itself the root canals were completed and measurement was taken for crowns for the back teeth and then the lower front teeth were removed. Since there was no infection in the area, soon after removal, immediate placement of 2 implants was done to replace the 4 missing teeth under the same anesthesia.

The next day, as the patient was feeling comfortable, temporization was done for the front teeth and the posterior crowns were also fixed. The third day, after the follow up checkup, he left the same evening.

After 5 months, he mailed us the latest OPG, showing stabilization of the implant. A local check up there confirmed he was ready for loading of the implants (crown placement) post which he scheduled his second visit.

On the first day of his second visit, the abutments (the top portion of implant resembling the prepared tooth) was fixed and impression taken and sent to the lab. The next day, a fitting trial of the fixed prosthesis was done and it was planned **to add gum ceramic** to the front two teeth to replace the missing gum height and after the trial on the fourth day the prosthesis was cemented onto the Implant abutments.



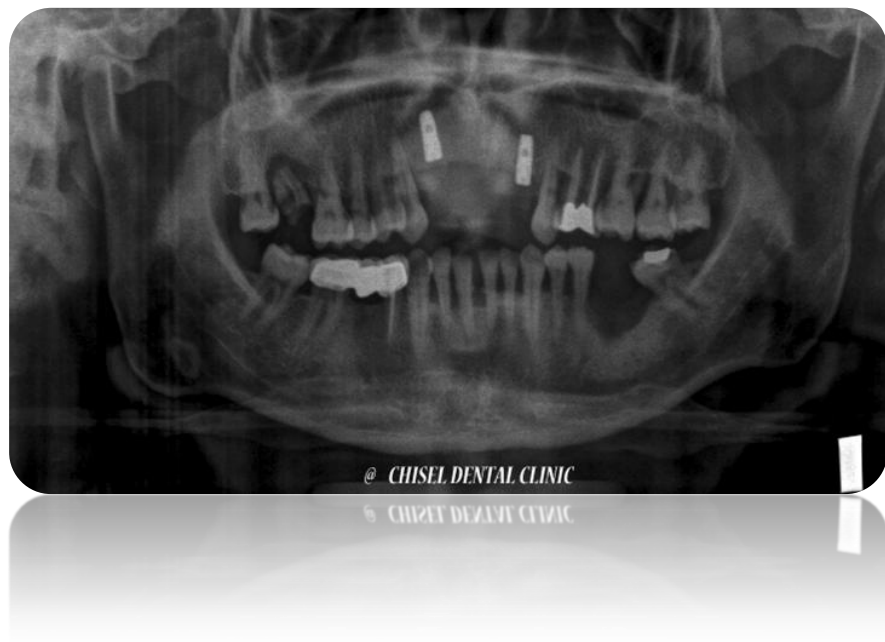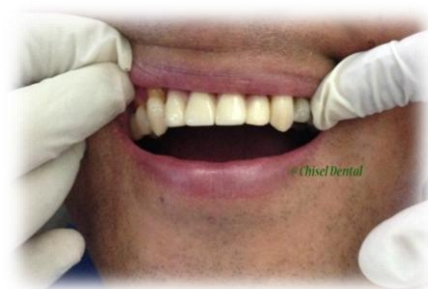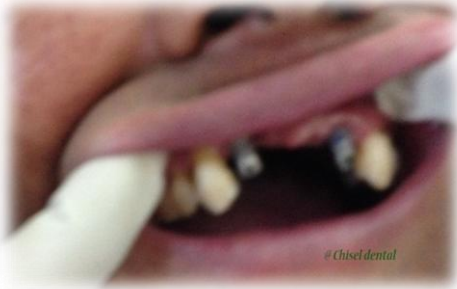Upper Front teeth Implant:

This young patient had lost his front four teeth and was looking for alternatives. Since he had already lost these front teeth he did not wish to touch any of his other normal teeth

and made a conscious decision of going in for implants. Firstly, impression was taken for temporary crowns and a through gum cleaning was done as it was required.

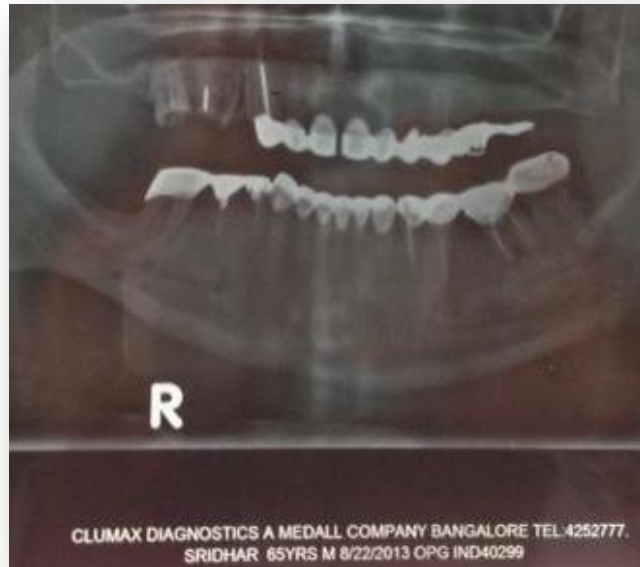Two implants (one on either side) were placed, the whole procedure completed in less than 30 mins, supervised by taking digital x-rays. The third day, checkup was done and removable prosthesis was given for the interim period.

After a 6 month recall x ray, the abutment was placed and final prosthesis was fabricated within 4 days for Implant supported Zirconia Bridge.

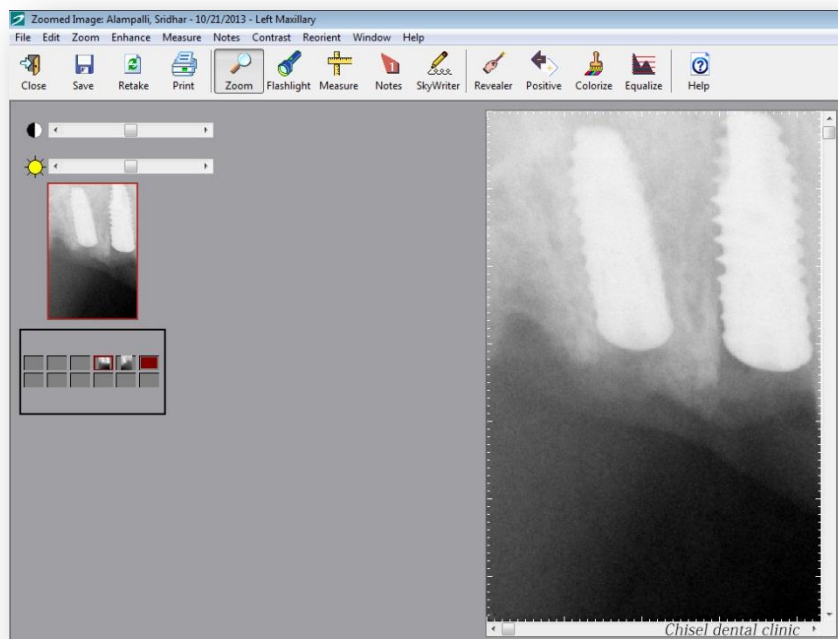


Posterior {back} teeth Implants:

When all the back molars on one side are missing, a minimum of two implants are sufficient to replace all the teeth on that side. The procedure and duration remains the same as in the above cases if the replacement is planned for immediately and implants can be placed immediately soon after extraction of the concerned teeth as with the upper right side of the following patient.



Now-a- days, with the advancement of **Digital RVG x-rays**, constant chair side evaluation of implant placement has eliminated the earlier so called mishaps or complications of implant placement



However, If the replacement is delayed and planned after a few years, sometimes in the upper jaw, the sinus (a balloon like structure) tends to shift down making the procedure slightly more complicated by requiring Sinus lift and bone graft placement as discussed in the case below.

POSTERIOR IMPLANTS: [Special considerations]

Sinus Lift with bone graft :

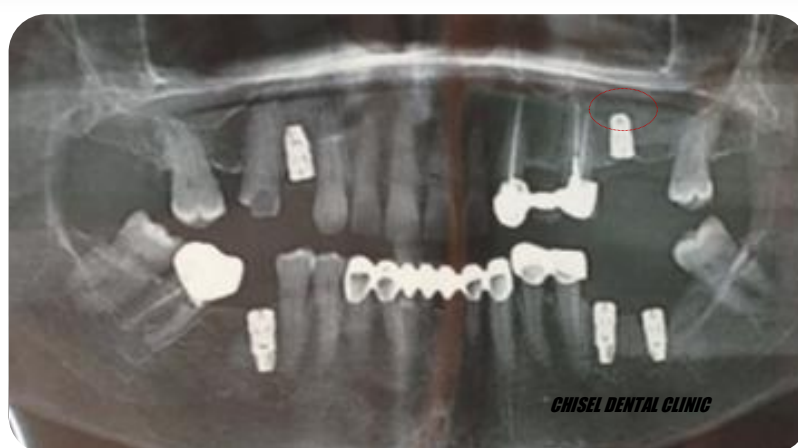
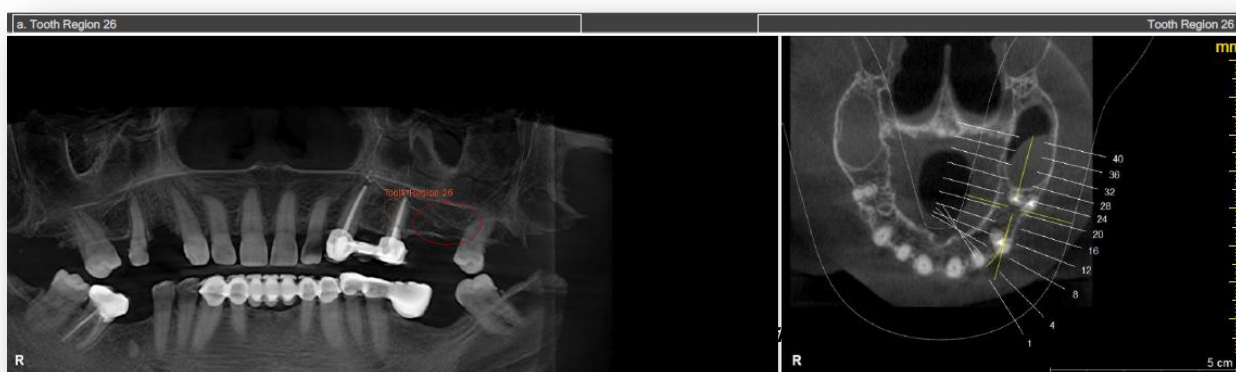
This patient had lost her behind teeth 5 yrs. ago and once she lost the other side too it set her looking for replacements. She could not go in for bridge as there was no last tooth.

On her consultation, her opg x ray showed reduced bone height in upper region and that the sinus had occupied that space. Hence a specialized 3D x-ray called **CBCT** was taken to check the exact height and width of bone for the treatment planning.

Then implant was placed in the other regions and in upper implant was placed following Sinus lift procedure along with bone graft mixed with PRF [Platelet rich fibrin] derived from the patient herself. Sutures were placed and pt. was recalled after 5 days for check-up. After a week, the sutures were removed and the area was allowed to heal.

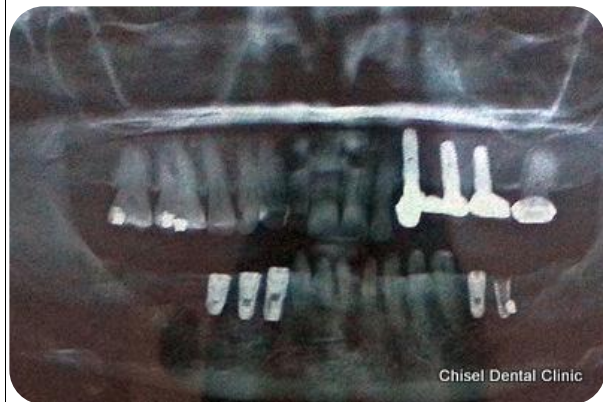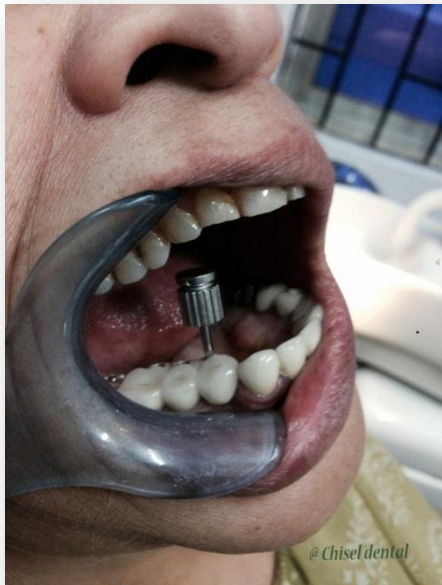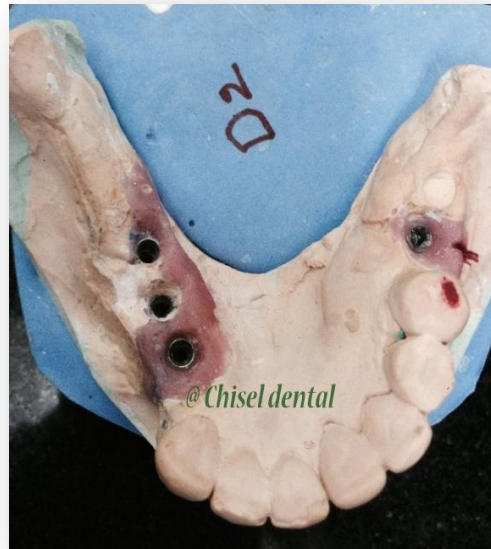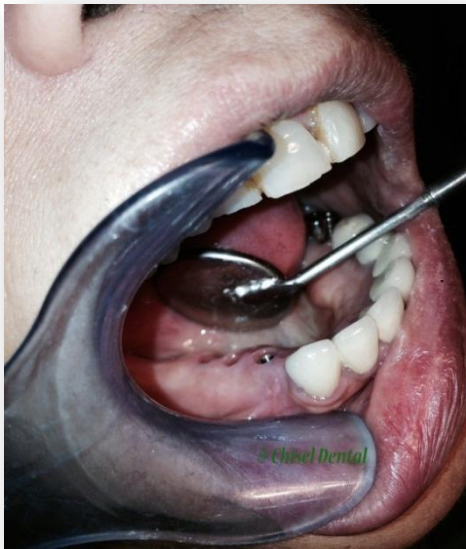
First follow up opg after 5 months showed that some more healing time was required for upper region and the lower showed appropriate stability. The prosthesis for the other teeth were fabricated by the end of 6 months while after 8 months the x-ray revealed that the implant had stabilized and fixed prosthesis was given for the upper.

Pre CBCT REVEALING POSITION OF SINUS FLOOR:



Implant supported bridge:

This 68yr old patient had her lower jaw completely inside, shrunken, and not in line with the upper arch. Few years ago, implants were completed for the upper and now she wanted to replace her lower back teeth also with implants... Though the implant procedure remained the same, in the planning stage itself, implants were placed in the area of strongest /ideal bone presence and the implant placement was designed to allow for angulated abutments that would ensure crowns could be placed in function with the upper teeth.



Chisel Dental Clinic

Full mouth rehabilitation with :-

✚ Implant supported Denture :-

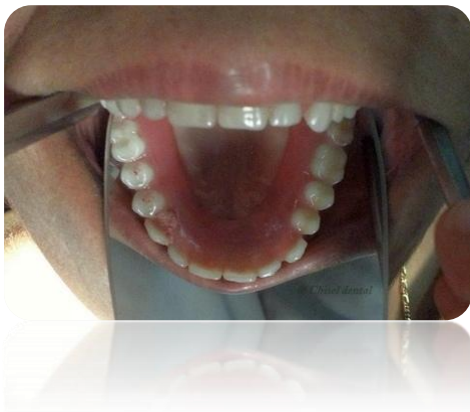Whenever all of the teeth are missing as in this case... treatment planning is essential with a complete discussion as to the patient's expectations. In this case patient was tired of her loose removable complete dentures and wanted good functionality most importantly in terms of chewing and equally important was that it be cost-effective.

Hence for her, the treatment plan arrived at; constituted placement of 4 implants on the upper to ensure a fixed hybrid denture which not being as heavy as a bridge does not require greater no. of implants but has really good ceramic esthetics and functionality with less coverage of tissue than a denture and for the lower only 2 implants were placed and a ball and socket type of semi-fixed denture was planned that was economical with acceptable esthetics and function.

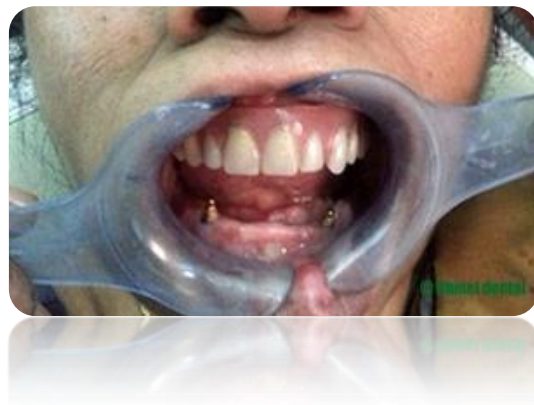All the implants were placed on the same day itself and a regular removable complete denture was fabricated as a temporary/interim denture for the healing period. After a period of 6 months the process of fabricating hybrid denture was initiated for the upper and for the lower jaw ball and socket type denture was fabricated.

Also in her case the teeth were customized to look older and slightly worn out as she wished it to match with her age and appearance.

UPPER IMPLANT SUPPORTED DENTURE



LOWER IMPLANT FOR BALL AND SOCKET DENTURE

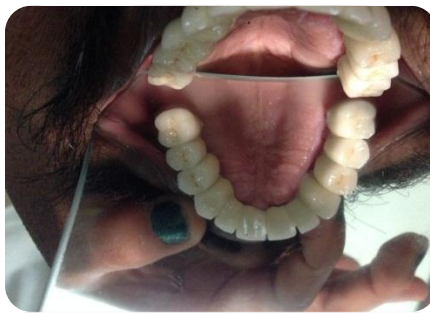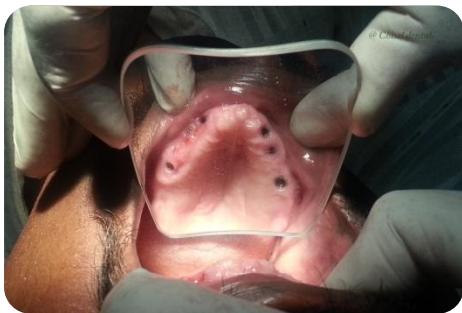
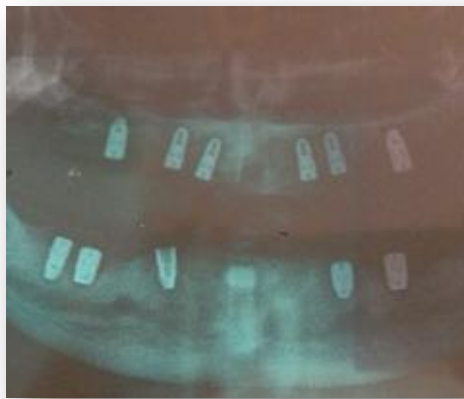
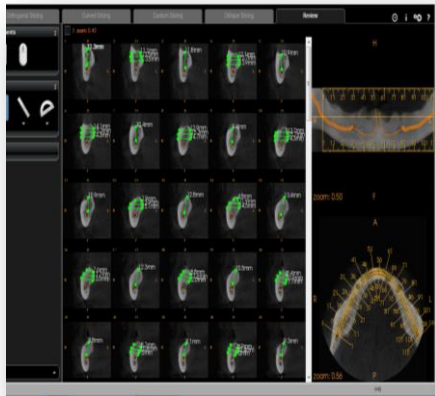



✚ Implant supported bridge:

Whenever a young person loses all his teeth, it is not necessary to wear a denture... This patient was averse to the term denture itself as he felt humiliated that at his age he had to wear dentures interim to the stage after removal of teeth. He wanted a permanent alternative.

In such cases, as a bridge takes more chewing load, it will require greater number of implants to take that loading. Here the minimum required i. e; 6 implants were placed in the upper and 6 months later the process of fabricating prosthesis was initiated after x ray evaluation.

To evaluate bone quality and anatomy a special 3-D CBCT scan was used which also detected an anatomical anomaly of the mandibular nerve.





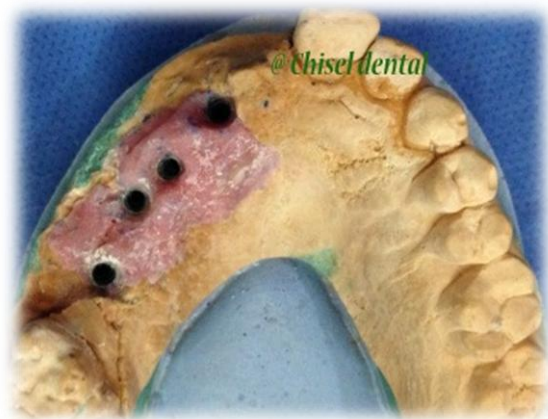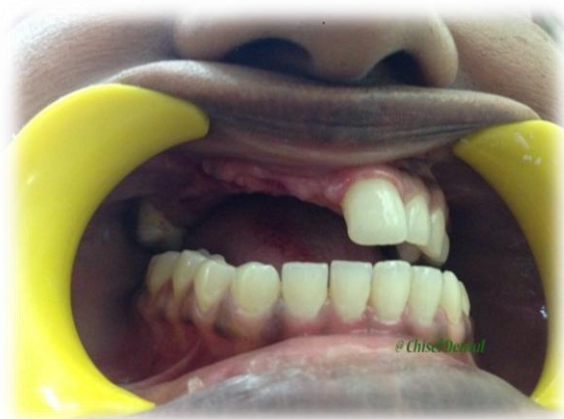MEDICALLY COMPROMISED CONDITIONS:

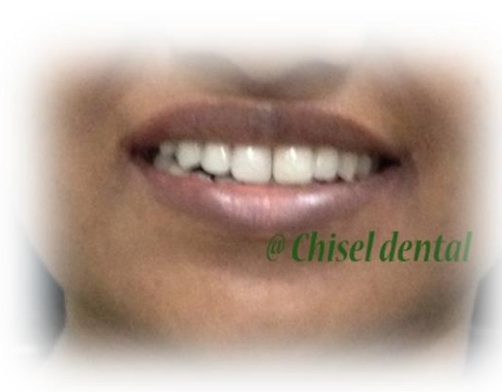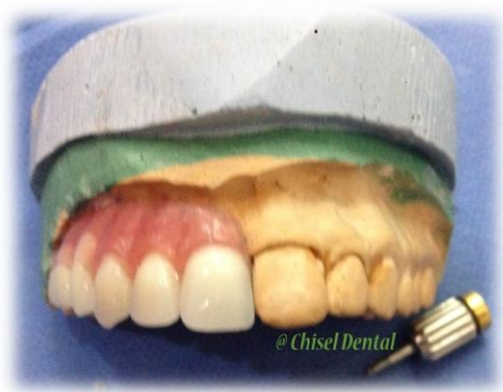Under General Anesthesia :

Severe Bone loss –

This Young 27 year old patient with history of an accident when she was 15years old was missing the entire right arch. Her history further revealed that she was wearing dentures for the past 12yrs which had completely eaten away the bone there. Most places she had been to were not giving her the alternative of an implant as it was a complicated long term treatment and the ones that did were out of her completely out of her budget plan.

For her firstly, tibia bone graft was planned and under gen. anesthesia, bone was taken from the leg bone and augmented in the maxillary bone region and recontoured. In 7months time, x ray revealed that bone was completely adapted and ready to take up implants. 4 implants were then strategically placed and the entire right side arch was rehabilitated over the next 6 months with completely fixed hybrid denture.





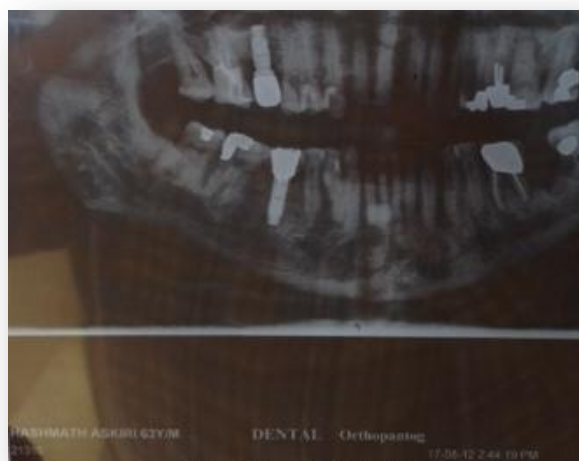
Elderly Patients [Medically Compromised – Diabetic and Heart disease]

Is Implant absolutely contraindicated if you are **Diabetic**?? Well, absolutely NOT! But yes, if you have uncontrolled high fluctuating Sugar levels, then that needs to be addressed first and any Medical procedure is avoided till then including implants.

When Mr. Askiri came to us he had his blood sugar levels on the higher end. He was first counseled on monitoring and trying to regulate his sugar levels in close co-ordination with the clinic as well as his physician and once it was monitored to be under control for 5 months continuously, Implants were placed and allowed to stabilize.

Throughout this time period, one needs to be under the physician's monitoring of sugar levels. For this interim period of 5 months, a high end valplast flexible partial denture was fabricated which he continued to use post implant placement till the crowns were given.

Once stabilized, the abutments and crowns were fixed.

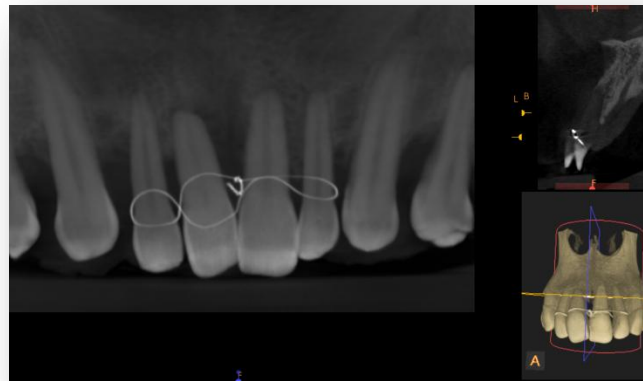


Even in patients with certain **heart** conditions such as valves etc, Implants can be placed successfully when utmost sterilization is maintained and care is taken while prescribing medications.

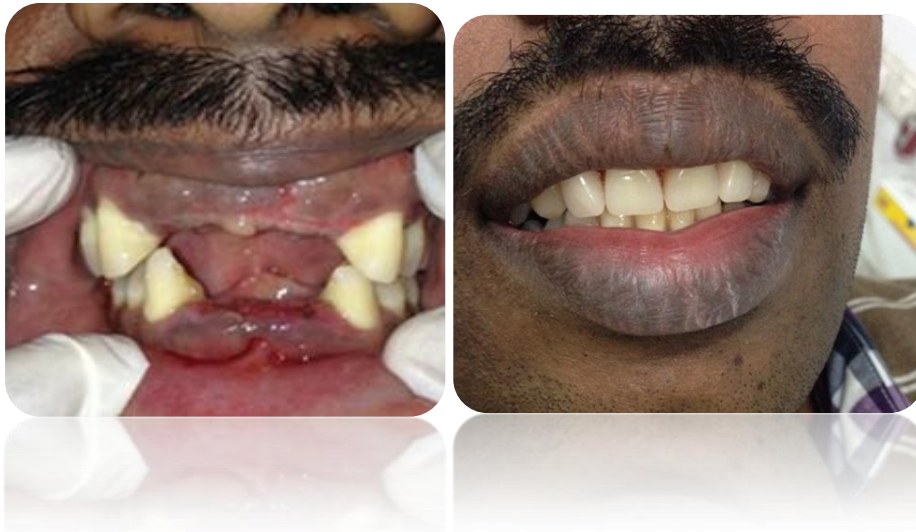Patients with Gum disease:

In Case You Have Weak Gums, Or Your Teeth are Loose and need to be removed, Then Can Implants Be done...

Yes it can. This patient had weak gums with bone loss. Hence first, prior to placing of implants, the gums were treated with laser treatment and gum surgery, followed by implant placement for the upper and then after monitoring the outcome of the upper implants , two more implants were also placed for the lower front teeth. The healing time was almost the same.



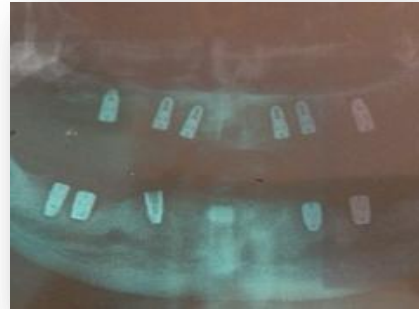
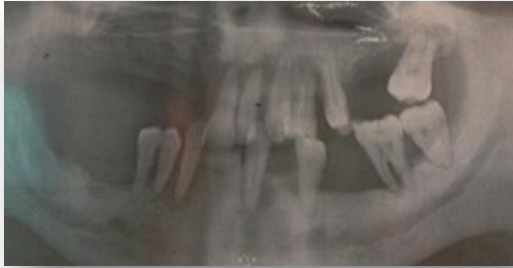Following implant stabilization, in his case a **Hybrid prosthesis** was given which did not transfer the whole load over the implants and also looked extremely natural.



Here, patient is advised to get periodontal evaluation done at least yearly thrice for maintenance.

Resorbed ridges:

Unlike a few years earlier, presently even patients with resorbed jaw bones can be rehabilitated with implant crowns/bridges or dentures with the advent of **Mini implants** designed for this very purpose.



However, what one needs to remember is that, as any delicate machinery needs servicing, so also the implant area needs to be maintained clean and for every 4-6 months regular dental check -ups to the dentist especially in cases like these can maintain them such that it can function for a lifetime...