

CASE REPORT

MANAGEMENT OF INTRINSIC DISCOLORATION - ADVANCED TREATMENT OPTIONS: CASE REPORT

Rashmi G. Shetty¹, Sumanth M. Shetty², Reema Srichand³, Litha⁴, Vishwanath G⁵

HOW TO CITE THIS ARTICLE:

Rashmi G. Shetty, Sumanth M. Shetty, Reema Srichand, Litha, Vishwanath G. "Management of Intrinsic Discoloration - Advanced Treatment Options: Case Report". Journal of Evolution of Medical and Dental Sciences 2014; Vol. 3, Issue 04, January 27; Page: 882-886, DOI: 10.14260/jemds/2014/1919

SUMMARY: Aesthetics of the teeth is of great importance to patients, including tooth color. Of the various causes of tooth discoloration fluorosis, enamel hypoplasia, medication staining etc. is commonly encountered. The treatment options for discoloration are varied depending on individual case basis. The purpose of this article is to report the advanced treatment options for generalized intrinsic discoloration encompassing power bleaching to veneers to full mouth rehabilitation with porcelain laminates and ceramic crowns.

KEYWORDS: Intrinsic discoloration, fluorosis, tetracycline staining, bleaching, veneers.

INTRODUCTION: Today's dental patients are better educated than in the past as various media have provided our patients with insights on the latest advances and research. One major area that our patients are requesting more information on is esthetic dentistry. Dental services to enhance personal appearances have increased over recent years. Patients are also no longer satisfied with simple bleaching procedures and insist on pearly white teeth as the final outcome.¹

The type of treatment instituted for patients with discoloration depends on patient's motivation towards dental treatment, the depth of discoloration and expectation of outcome.² Here, three case reports are presented of patients with different degrees of discoloration and expectation of outcomes treated by power bleaching, composite veneers and porcelain veneers and full crowns respectively.

CASE REPORT A: A patient named Dijeesh aged 26 reported with a complaint of severely discolored teeth. He presented a history of discoloration since childhood. On examination the case was diagnosed as moderate to severe fluorosis according to Dean's fluorosis index. [Fig.1 (A)]

The case was treated by Power bleaching using Laser power and 35% hydrogen peroxide as bleaching agent.^{3, 4} Following oral prophylaxis, isolation was achieved using Opal dam and tissue retractors. Vaseline was used on the lips. Isolation from the caustic acid is of utmost importance in power bleaching. In this technique, laser light activates the bleaching agent. A fresh mix of gel was placed over the teeth and left in cycles of 10 mins each. [Fig 1(B)] The gel was suctioned off the teeth and the teeth wiped using damp gauze. A further fresh mix was then applied, activated and left for the same length of time. ⁵ At the end of three activation cycles of 10mins each, the patient was happy with the results [Fig 1(C)].

CASE REPORT B: Manohar, aged 28, reported to our hospital with a complaint of rough discolored teeth. On examination the case was found to be moderate to severe fluorosis according to Dean's fluorosis index with pitting and banding of enamel observed. [Fig.2 (A)]

CASE REPORT

Treatment was carried out by giving direct composite resin veneers from 13 -23 because of the time and financial constraints of the patient and his expectation out of the treatment for smoother whiter teeth ⁶. Bleaching was not an option in this case due to the surface roughness and banding present which dictated an invasive procedure⁷. The treatment involved veneer preparation (window preparation)⁸, [Fig 2(B)] etching and bonding with Prime & bond followed by buildup using nano-composite ceram-X duo (Dentsply India) and polishing with Super snap (Shofu Inc., Japan). The patient got the desired result and was satisfied with the treatment. [Fig 2(C)]

CASE REPORT C: Patient named Shabbir, aged 29 reported with a complaint of severely discolored teeth. He was aware that his discoloration was due to the medication Tetracycline. On examination severe brownish to bluish discoloration of tooth with banding was observed. [Fig 3(A)].

The discoloration was generalized and the patient had high expectations out of the treatment with respect to alteration of the esthetics. Hence the treatment plan was construed to go ahead with Porcelain laminates for the upper anteriors from 13-23 and all-ceramic crowns for the lower anteriors 33-43 and first premolars as his occlusion was not favorable for laminates with lower.^{9,10} Pre operative impressions were taken, veneer and crown preparations were carried out followed by temporaries given on the same day¹¹. The veneers and crowns were luted in the next sitting using Rely X U-100 adhesive resin cement¹². [Fig 3(B)] The patient got the desired results and was happy with the treatment. [Fig 3(C)]

DISCUSSION: In case A, power bleaching was opted for as it gives immediate results in about an hour. In this technique, heat source, is replaced with plasma arc lamps, LED lights, or lasers. The dentist here has complete control throughout the procedure and is able to stop when the desired shade is achieved. Power bleaching works by the permeation of oxygenating per hydroxyl free radicals through enamel micro pores along a diffusion gradient and into the dentine where it oxidizes the stains and thereby bleaches the teeth.^{3,4} The main advantages of this technique are that it produces immediate results and avoids problems with home bleaching procedures such as gag from trays and there is no problem of distaste as for home bleaching gel. The biggest disadvantage is the caustic nature of the 35-50% hydrogen peroxide. The need for a meticulous protocol in handling, applying, removal and disposal of these materials is essential.⁵

In case B, Because of the time and financial constraint given by patient, direct composite veneer treatment option was selected⁶. Veneers have been successfully employed for management moderate grade fluorosis. Advantage of direct composite veneer is that it is done with minimal chair time compared to indirect veneers. The only disadvantage being its wear & color stability which the patient was made aware of, that it might have to be replaced over the years ⁸.

In case C, patient had severe discoloration and a high motivation to undergo the best treatment. The treatment of restoring severe tetracycline discoloration patients with porcelain laminates and metal free crowns requires careful preparation.¹² Sensitivity of the teeth should be observed for and preparation should be limited to minimal depth required. It is very important to ask the lab to place a masking layer while fabricating the laminates. Bleaching prior to tooth preparation is also an option in case of mild discoloration.⁹ Advantage of this procedure is that the desired aesthetic results and functional efficiency is achieved on a long term basis.

CASE REPORT

In each of the treatment options described above, each one has its own advantages and disadvantages. A good clinician should be aware of all the treatment options available, assess its merits and demerits and select the best treatment option according to individual patient needs and desires.

CONCLUSION: Intrinsic discoloration of teeth is a major aesthetic problem. Our society tends to dislike yellowing of teeth that comes with age or stains. White teeth are not only attractive but are also indicative of nutritional health, self-esteem & hygiene¹. The purpose of this article was to report various advanced treatment options for discolored teeth from a conservative bleaching management to extensive full veneer/crown restorations. So it is in the interest of both patient and dentist that the dentist be aware of all the treatment modalities available to us. Newer treatment options which combine these various treatment modalities are also emerging. However, the severity of the lesion alone determines the treatment option.

REFERENCES:

1. Strassler, Howard E. Vital Tooth Bleaching: An Update: M dental Continuing Education Course. Cont Ed Insert Fall 2006; 4: 1- 8.
2. Sherwood IA. Fluorosis: Varied treatment options: J Conserv Dent: Jan/Mar. 2010; 13 (1): 47-53.
3. Grace Sun. Lasers and light Amplification in dentistry, 2004, 1st Ed.; p-56
4. Ingle, Bakland. Endodontics, Fifth edition 2004; p-386
5. ADA Council on Scientific Affairs. Laser-Assisted Bleaching. An Update: JADA, Oct. 1998; 129 (10): 1484-1487.
6. Roberson, Heymann, Swift. Sturdevant's Art and Science of Operative dentistry. Missouri: Mosby, 2002; 4th ed. p. 610-20.
7. Akapata ES. Occurrence and management of dental fluorosis. Int Dent J 2001; 51: 325-33.
8. Aschheim, Dale: Esthetic dentistry: A Clinical approach to esthetic dentistry and Materials. 2001; 2nd Ed: 435-438.
9. Ng F, Manton DJ. Aesthetic management of severely fluorosed incisors in an adolescent female. Aust Dent J 2007; 52(3):243-8.
10. Mount GJ, Hume WR. Preservation and Restoration of tooth structure, Mosby International Ltd, 1998; 1st Ed.: 186-193.
11. Mohl, Zarb, Carlsson, Rugh. A textbook of occlusion. Prosthodontic, operative and orthodontic therapy. Illinois. Quintessence Books; 1988: p. 305-24.
12. Ardu S, Stayridakis M, Krejci I. A minimally invasive treatment of severe dental fluorosis. Quintessence Int 2007; 38: 455-8.

CASE REPORT

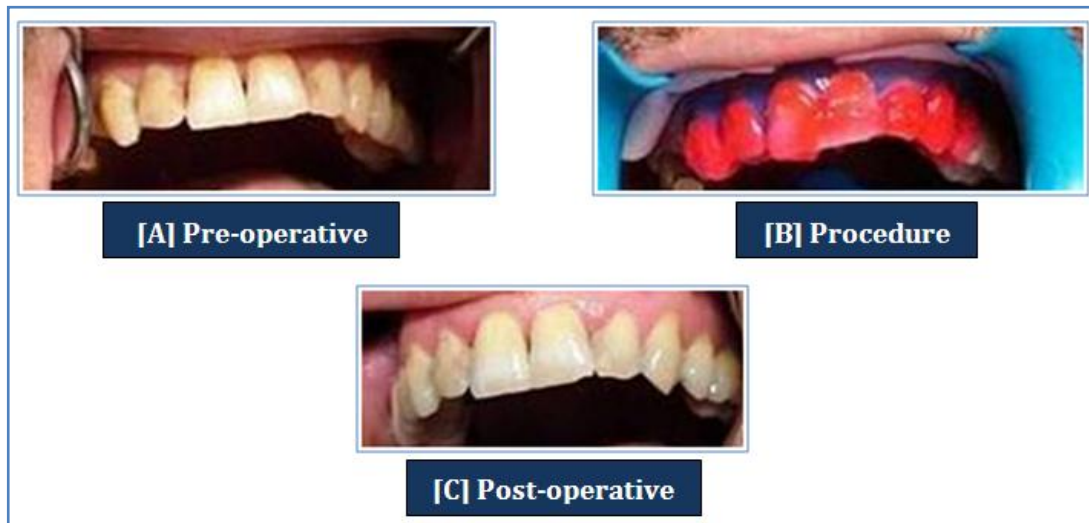


Fig. 1: Intraoral photograph showing Laser Bleaching.

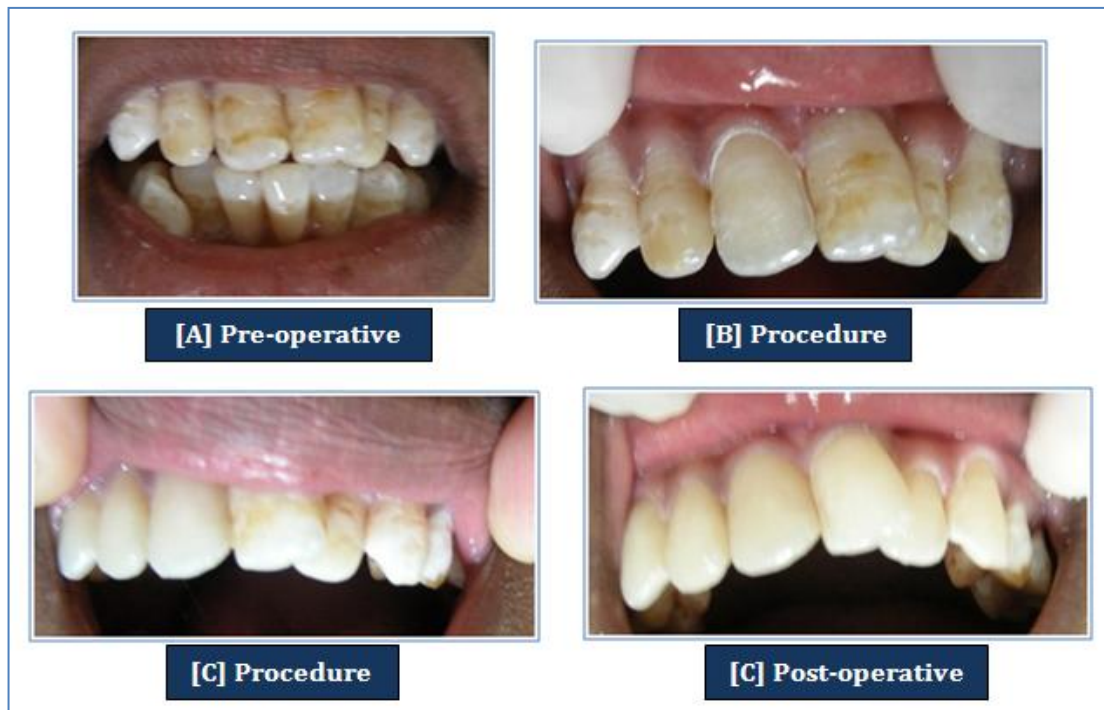


Fig. 2: Placement of Composite veneers.

CASE REPORT

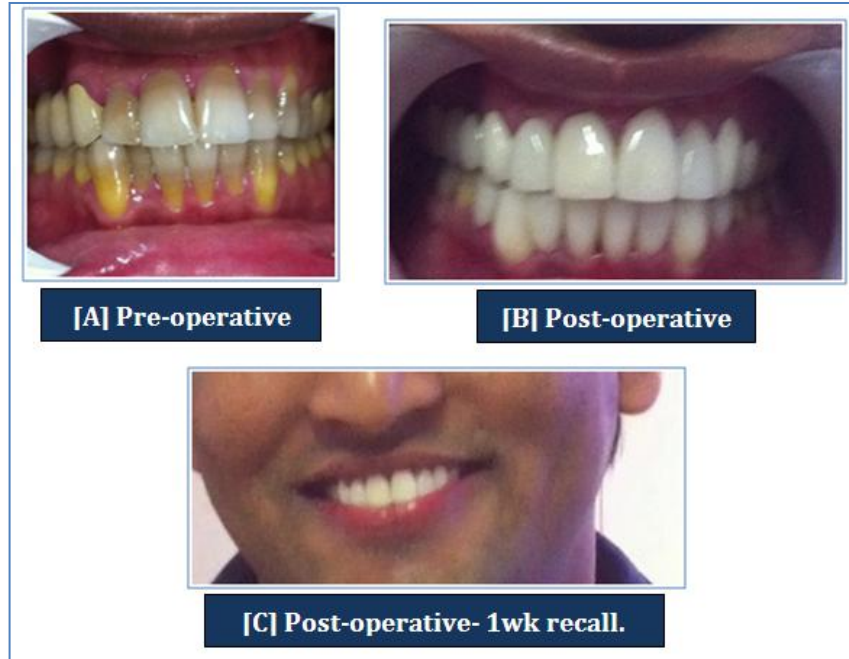

Fig. 3: Treatment of Tetracycline staining – Porcelain veneers.

AUTHORS:

1. Rashmi G. Shetty
2. Sumanth M. Shetty
3. Reema Srichand
4. Litha
5. Vishwanath G.

PARTICULARS OF CONTRIBUTORS:

1. Assistant Professor, Department of Conservative Dentistry and Endodontics, SGT Dental College, Gurgaon.
2. Associate Professor, Department of Pedodontics, T.M.U. Dental College, Moradabad, U.P.
3. Prosthodontist, Department of Restorative Dentistry and Endodontics, Chisel Dental Clinic, Bangalore.

4. Assistant Professor, Department of Oral Pathology, Farooquia Dental College, Mysore.
5. Orthodontist, Department of Restorative Dentistry and Endodontics, Chisel Dental Clinic, Bangalore.

NAME ADDRESS EMAIL ID OF THE CORRESPONDING AUTHOR:

Dr. Rashmi G. Shetty,
Chisel Dental Clinic,
#224, 1st Main, 7th Block,
Near Forum Mall, Koramangala,
Bangalore – 95, Karnataka.
E-mail: drrashmishetty@gmail.com

Date of Submission: 25/12/2013.
Date of Peer Review: 26/12/2013.
Date of Acceptance: 11/01/2014.
Date of Publishing: 22/01/2014.